

Large Accessory Scrotal Spleen Masquerading as Testicular Tumor

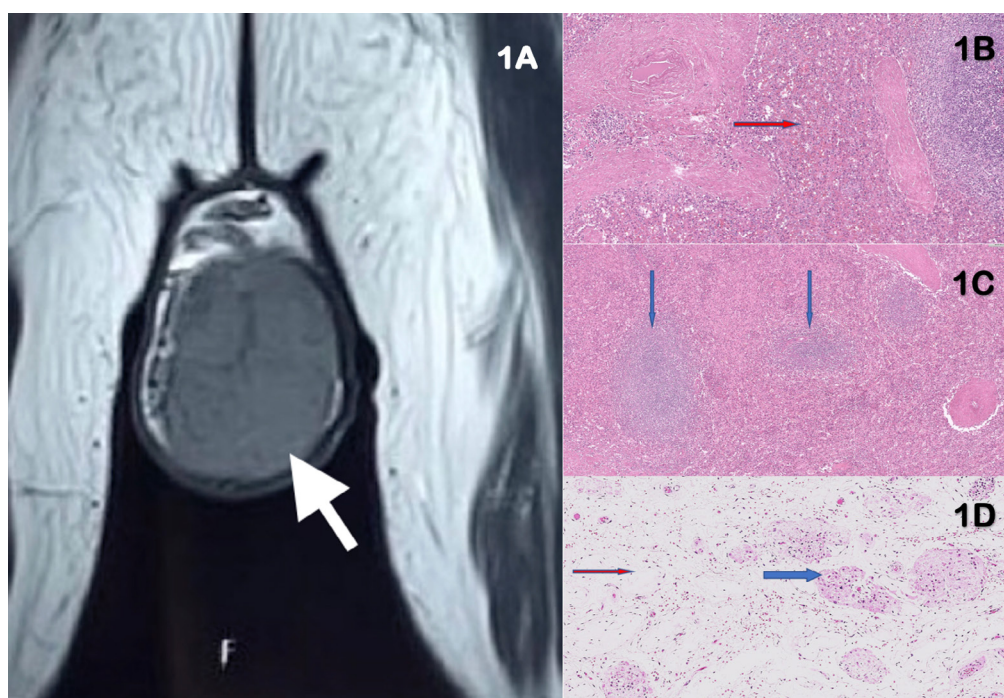
 Sirish Bharadwaj,¹  Sanjay Sinha,^{✉1}  Meenakshi Swain²

¹Department of Urology, Apollo Hospital, Hyderabad, India ²Department of Pathology, Apollo Hospital, Hyderabad, India

A 75-year-old male presented with left scrotal swelling of 1 year's duration. The firm, non-tender swelling was indistinct from the testis and consistent with left testicular tumor. Serum alpha fetoprotein, beta-human chorionic gonadotropin, and lactate dehydrogenase levels were normal. Scrotal ultrasonography and MRI showed 8.4x5.0x4.0cm mass in the left scrotum without calcification or necrosis (**Figure 1A**). The left testis could not be identified separately. A possibility of spermatocytic seminoma or lymphoma was considered. Left high inguinal orchidectomy was performed with uneventful recovery. At histopathology, the entire mass was noted to be an accessory spleen with adjoining atrophic compressed testicular tissue (**Figures 1B,C,D**).

FIGURE 1.

Large accessory scrotal spleen. MRI of the scrotum showed a large 8cm left scrotal mass (white arrow) (A). The testis could not be identified separately. Histologic images showed splenic tissue (B, C) adherent to the tunica albuginea but not enveloped by it (hematoxylin and eosin staining; 5x magnification in B, and 10x in C; blue arrows show white pulp; red arrow shows red pulp with sinusoids) and adjoining atrophic testicular tissue (D) with clusters of Leydig cells (red arrow) and atrophic seminiferous tubules (red arrow; hematoxylin and eosin staining; 10x)



Key Words

Accessory spleen, testicular tumor, scrotal swelling, splenogonadal fusion

Competing Interests

None declared.
Patient consent: Obtained.

Article Information

Received on April 22, 2022
Accepted on April 24, 2022
Soc Int Urol J. 2022;3(5):354–355
DOI: 10.48083/CTUZ3597

Accessory splenic tissue is a common finding noted in 2% to 35% of individuals most often in and around the splenic hilum[1]. It can be classified as continuous or discontinuous with the spleen[2]. Accessory splenic tissue presenting as a scrotal mass is very rare[1]. Splenic tissue reaches the scrotum as a result of spleno-gonadal fusion, typically on the left side with tissue enveloped or adherent to the tunica albuginea[3].

This case is unusual because of the age of presentation, relatively short history, and large size of the mass. Most men present as young adults[2,3]. Surgery is unnecessary if the diagnosis can be made preoperatively[4]. Making

a preoperative diagnosis to avoid surgery is practically difficult unless the patient can categorically state that the mass has been present and stable for years. In such a setting, Doppler imaging showing a hyper-vascular upper polar mass[1] confirmed by splenic scintigraphy using technetium-Tc99m[2] may help avoid surgery. Intraoperative frozen section histology might help avoid orchidectomy if exploration is deemed unavoidable[3,4]. The short history in our patient is difficult to explain. Patients with splenic disease such as leukemia or malaria may show concurrent increase in size of the accessory spleen[2]. However, our patient did not show any such disease.

References

1. Marwah N, Bhutani N, Kalra R, Kajal P. Accessory spleen within the scrotum. *J Pediatr Surg Case Rep*.2019 Mar 1;42:19-23.
2. Kadouri Y, Carnicelli D, Sayegh HE, Benslimane L, Nouini Y. Pathogenesis, diagnosis, and management of splenogonadal fusion: a literature review. *Case Rep Urol*.2020 Oct 7;2020:8876219.
3. Huang G, Huang Y, Zeng L, Yuan M, Wu Y, Huang L. Continuous-type splenogonadal fusion: a case report. *Exp Ther Med*.2017 May;13(5):2019-2021.
4. Abokrecha A, Almatrfi A. Discontinued splenogonadal fusion and bilateral empty scrotum in an 18-month-old boy. *European J Pediatr Surg Rep*.2017 Feb;5(1):e1-e3.