

# CD34 and FSHR Expression to Differentiate Multiple Subtypes of Benign and Malignant Renal Neoplasms

Giancarlo Marra,<sup>✉1,2</sup> Didier Meseure,<sup>3</sup> Marine Lefèvre,<sup>2</sup> Andre Nicolas,<sup>3</sup> Laetitia Lesage,<sup>3</sup> Nicolae Ghinea,<sup>4</sup> Marco Moschini,<sup>1</sup> Caio Pasquali,<sup>1</sup> Petr Macek,<sup>1</sup> Claudia Filippini,<sup>2</sup> Paolo Gontero,<sup>2</sup> Rafael Sanchez-Salas,<sup>1</sup> Xavier Cathelineau<sup>1</sup>

<sup>1</sup>Department of Urology, Institut Mutualiste Montsouris and Université Paris Descartes, Paris, France <sup>2</sup>Department of Urology and University of Turin, Turin, Italy <sup>3</sup>Platform of Experimental Pathology, Department of Diagnostic and Theranostic Medicine, Institut Curie, Paris, France <sup>4</sup>Department of Pathology, Institut Mutualiste Montsouris, Paris, France

## Abstract

**Background** Currently, no markers accurately differentiate benign from malignant renal masses. CD34 and FSHR are transmembrane proteins involved in neo-angiogenetic pathways and are differently expressed in several normal and cancerous tissues. However, little evidence exists on their distribution in different renal tumors. We aimed to evaluate their expressions in various renal tumors and adjacent normal tissue.

**Methods** We retrieved 810 histological samples from 26 patients who underwent surgery for suspected RCa. In each case a core of 10 × 1 mm was selected perpendicular to the tumor capsule between normal kidney and tumor. Within this core 30 regions of interest (ROI), each measuring 669 μm × 500 μm, were acquired at 20× magnification (n = 2 adjacent normal tissue; n = 2 tumor capsule; n = 26 tumor). The surface area of FSHR and CD34 immunostaining was quantified in each ROI using number of stained pixels. The results were compared between RCa and normal kidney.

**Results** Immunostaining was significantly different in normal, tumor capsular, and tumor tissues (both CD34 and FSHR  $P < 0.0001$ ), with overall highest expression in normal and lowest in tumor tissues, where CD34 and FSHR were differently expressed amongst different tumor subtypes (both  $P < 0.0001$ ). CD34 and FSHR were more expressed in benign versus malignant (both  $P < 0.0001$ ) and in chromophobe carcinoma versus oncocytoma tumor tissues (CD34  $P = 0.0003$ ; FSHR  $P < 0.0001$ ). The discriminating ability of FSHR alone for benign versus malignant (AUC 0.805; 95% CI 0.771 to 0.837) and chromophobe carcinoma versus oncocytoma (AUC 0.973; 95% CI 0.939 to 0.991) was high. In both cases FSHR AUC was significantly higher than CD34 (both  $P < 0.0001$ ) and equivalent to the combination of CD34 and FSHR (both  $P > 0.9$ ). The correlation amongst levels of staining in tumor tissues and distance from the capsule were overall weak (Spearman coefficient CD34 to 0.0644; FSHR-0.16322).

**Conclusion** CD34 and FSHR are differentially expressed across renal tumor subtypes and between tumor and surrounding tissues. FSHR expression alone may be a useful tool to differentiate benign from malignant tumors and chromophobe carcinoma from oncocytoma.

## Introduction

Neo-angiogenesis is an important process for malignant and benign tumors growth and progression, allowing unrestricted expansion[1,2]. CD34 and follicle-stimulating hormone receptor (FSHR) are transmembrane proteins present in endothelial cells on the surface of blood vessels and differently expressed in several normal and cancerous tissues[2].

### Key Words

Kidney cancer, CD34, FSHR, tumor markers

### Competing Interests

None declared.

Funding Statement: Dr Giancarlo Marra's work at Institut Mutualiste Montsouris and at Institut Curie has been funded by a grant from the European Urology Scholarship Programme (EUSP).

### Article Information

Received on August 22, 2021  
Accepted on January 15, 2022  
This article has been peer reviewed.  
Soc Int Urol J. 2022;3(3):132–143  
DOI: 10.48083/RQBN1626

## Abbreviations

AML angiomyolipoma  
ChC chromophobe carcinoma  
FSHR follicle-stimulating hormone receptor  
RCa renal cancer  
RCC renal cell carcinoma

CD34 is an intercellular adhesion and cell-surface glycoprotein present in hematopoietic progenitor cells and endothelial vascular and lymphatic cells[2,3]. Although its specific function is not yet precisely characterized, CD34 is a pan-endothelial marker, and anti-CD34 antibodies are highly sensitive for endothelial differentiation. CD34 is differentially expressed in neoplastic and normal endothelium and/or may yield a prognostic value for several cancers including cervical[2], gastric[4] hepatoellular[5], prostate[6,7], kidney[8], bladder[9], and other neoplasms.

FSHR is a glycosylated transmembrane protein of the G protein receptors family, normally found in human testis Sertoli and ovarian granulosa cells[10,11]. Its presence has also been demonstrated in other tissues including osteoclasts, monocytes, endometrial cells, and the thyroid and the prostate glands, where, however, its expression is usually limited[11]. On the contrary, several malignancies—ovarian[12], prostate[13,14], breast[15], and others[15,16]—are found with FSHR expression. Although in cancer cells FSHR presence has been shown to vary depending on tumor type, its expression is constant in the endothelial cells within several cancers[11].

Kidney cancer is not infrequent, currently representing the sixth and eighth commonest cancer in men and women respectively, with more than 70 000 new cases detected yearly in the US[17]. In recent years, renal cancer (RCa) diagnosis has undergone a shift, with more than 60% of cases being diagnosed in the form of incidental small renal masses when abdominal imaging is performed for other investigations[18]. These renal lesions can be benign or malignant, and the RCa can vary widely with respect to prognosis. Conventional imaging, including CT and/or mpMRI, despite being currently able to identify renal masses, cannot reliably distinguish benign angiomyolipoma (AML) with minimal fat and oncocytoma from malignant lesions[19–21]. This diagnostic challenge holds even more true for oncocytoma as even when renal biopsies are performed, final histology of the surgical specimens confirms oncocytic neoplasms in only about 64.6% of cases, with the remaining tumors being mainly chromophobe carcinoma (18.7%)[22].

Although several attempts have been made, to date no molecular markers are able to reliably differentiate benign from malignant renal lesions[23]. Some studies previously detailed CD34 and FSHR expression in renal tissues and renal cell carcinoma (RCC), but overall, little to no evidence exists on their distribution in different RCa[11,24]. Furthermore, as they are expressed in tumor endothelial cells and involved in neo-angiogenetic pathways at multiple levels, they represent a potential target for molecular imaging with specific contrast agents and for novel therapeutic agents[1,2,10,11].

Our aim was to perform a preliminary evaluation of CD34 and FSHR expression in surgical specimens of different types of benign and malignant renal neoplasms and surrounding normal tissues and to detail their ability to differentiate amongst different subtypes of renal neoplasms.

## Materials and Methods

### Patients and tissue analysis

We retrieved histological samples from 26 patients who underwent surgical removal of a renal tumor including chromophobe RCC (n = 4), type 1 papillary RCC (pRCC1; n = 3), type 2 papillary RCC (pRCC2; n = 3), clear cell RCC (ccRCC; n = 9), oncocytoma (n = 6), and AML (n = 1). Paraffin-embedded tissue blocks were retrieved from the archives of the Department of Biopathology, Institut Mutualiste Montsouris, Paris, France.

### Immunohistochemistry

Immunohistochemistry assay was performed using FSHR-A02 antibodies (homemade antibody, mouse monoclonal, at 0.2 µg/mL for 30min at RT) and CD34 antibodies (DAKO ref:M7165, mouse monoclonal Qbend-10, at 1/200 for 30min at RT).

All immunostainings were processed using a Leica BOND RX research automated immunostaining device. Heat induced antigen retrieval was performed using citrate pH6 buffer (FSHR) and EDTA pH9 buffer (CD34). Immunodetection was performed using Leica Bond Polymer Refine detection kit according to the manufacturer's instructions. Antibodies specificity was confirmed on a panel of human testis tissue.

### Quantitative analysis

FSHR and CD34 labeled whole slides were scanned with the Perkin Elmer Vectra 3 scanner at ×10 magnification. Sections of 3 µm were cut with a microtome perpendicularly from the paraffin-embedded tissue block, including samples from the normal kidney, the tumor capsular zone, if present, and the kidney tumor. In each case, a core of 10 mm (depth) × 1 mm (width) was selected perpendicular to the capsule between normal

kidney and tumor to simulate a biopsy core. Within this core, 30 regions of interest (ROI), each measuring  $669 \mu\text{m} \times 500 \mu\text{m}$ , were acquired at  $20\times$  magnification. Two ROI were analyzed from normal kidney, 2 from the tumor capsular zone, when present, and 26 from the tumor (Figure 1). These ROI were then analyzed using the Perkin Elmer inForm software, which made it possible to determine the number of positive pixels for the DAB and thus to know the percentage of FSHR and CD34 labeled surface. Recorded variables included FSHR and CD34 staining, distance from the capsule and/or normal tissue, and tumor type. Figure 2 and Figure 3 display examples for the different tumors that were assessed according to ROI type for CD34 and FSHR immunostaining, respectively.

### Study aims

Our primary aim was to evaluate expression of CD34 and FSHR in different types of renal neoplasms including surrounding normal tissues, tumor capsular tissue, and tumor tissue.

Secondary aims were to evaluate whether CD34 and FSHR are differentially expressed in and can discriminate between (1) malignant versus benign renal tumor; (2) oncocytoma versus chromophobe carcinoma.

### Statistical analysis

Summary data were presented as median and interquartile range for continuous variables and as frequency and percentages for categorical variables. In univariate analysis, continuous variables were compared with the use of Wilcoxon-Mann-Whitney or Kruskal-Wallis test as appropriate. Spearman's coefficient was used to evaluate correlation between CD34 and FSHR immunostaining in cancerous tissues depending on the

distance from the capsule. To investigate the ability of biomarkers to discriminate benign from malignant tumors and oncocytoma from chromophobe carcinoma, CD34 and FSHR immunostaining values in cancerous tissues and the combination of both were used to perform different receiver-operating characteristics curves (ROC). Results are given as area under the curve (AUC) and 95% confidence interval (CI). Comparison between AUC was performed using DeLong's test. All tests were two-tail, and the level of statistical significance was set at 0.05. All the analyses were performed with SAS software, version 9.4 (SAS Institute Inc., Cary, US).

## Results

### Baseline analysis

We analyzed 810 tissue samples, including 210 (26%) benign and 600 (74%) malignant tumors. The majority of samples were from tumor tissues ( $n = 702$ ) and a minority from tumor capsular ( $n = 54$ ) or normal ( $n = 54$ ) tissue surrounding the cancer. Immunostaining values for CD34 and FSHR stratified by tumor subtype and tissue source (normal adjacent tissue, tumor capsule or tumor) are displayed in Figure 4A-B.

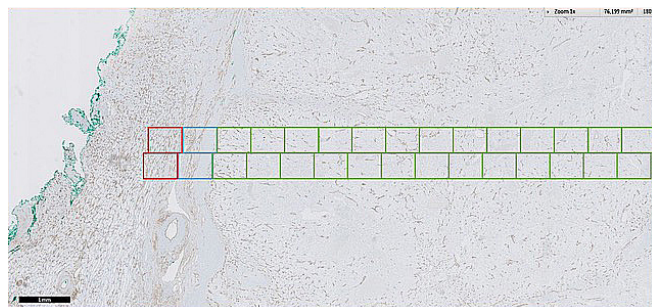
### Overall distribution of CD34 and FSHR in normal, capsular, and tumor tissues

Table 1 displays immunostaining values of CD34 and FSHR depending on tumor subtypes and malignant or benign diseases. Overall, we observed immunostaining was slightly but statistically significantly different in normal, tumor capsular, and tumor tissues (both CD34 and FSHR  $P < 0.0001$ ), with overall highest expression in normal tissues and lowest expression in cancerous tissues. Expression was always higher in normal and tumor capsular tissues compared with tumor tissues with the exception of CD34 for chromophobe carcinoma.

Overall, capsular CD34 and FSHR did not yield significant differences amongst different tumors with CD34 ranging from 4.47 for pRCC2 to 11.16 for pRCC1 ( $P = 0.1450$ ) and FSHR ranging from 1.05 for AML to 5.25 for oncocytoma ( $P = 0.14$ ). CD34 expression was different amongst normal adjacent tissue from different tumors (range 6.98 for ccRCC to 13.33 for AML;  $P = 0.0196$ ) while FSHR did not yield any significant differences (range 0.92 for AML to 4.65 for oncocytoma;  $P = 0.1120$ ). CD34 and FSHR were significantly differently expressed across the different tumor tissues (both  $P < 0.0001$ ). The range was relatively wide for CD34 (from 1.45 for pRCC1 to 8.72 for chromophobe carcinoma), whereas FSHR always had a mean staining percentage  $< 0.9$  with the exception of oncocytoma (4.28).

### FIGURE 1.

Tissue sampling methodology for CD34 and FSHR quantification



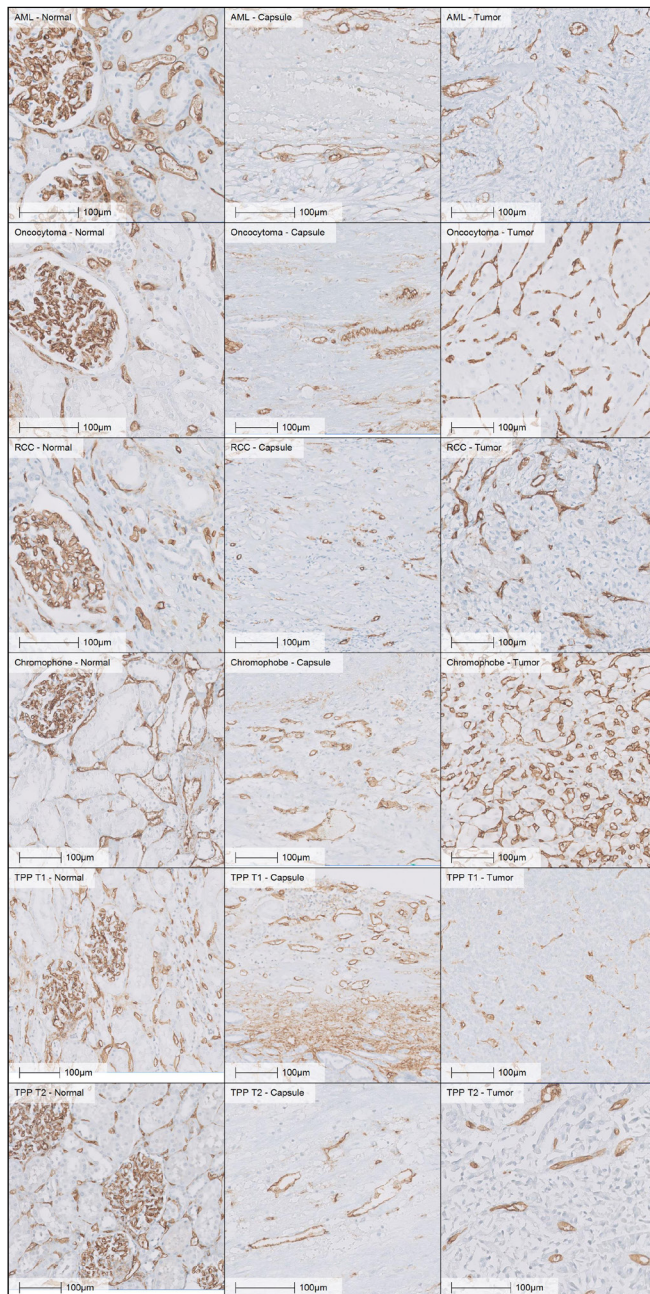
For each case acquisition of 30 zones of  $669 \mu\text{m} \times 500 \mu\text{m}$  (10 mm depth  $\times$  1 mm width) was performed.

Red: normal surrounding tissue; blue: capsular tissue; green: tumor tissue.



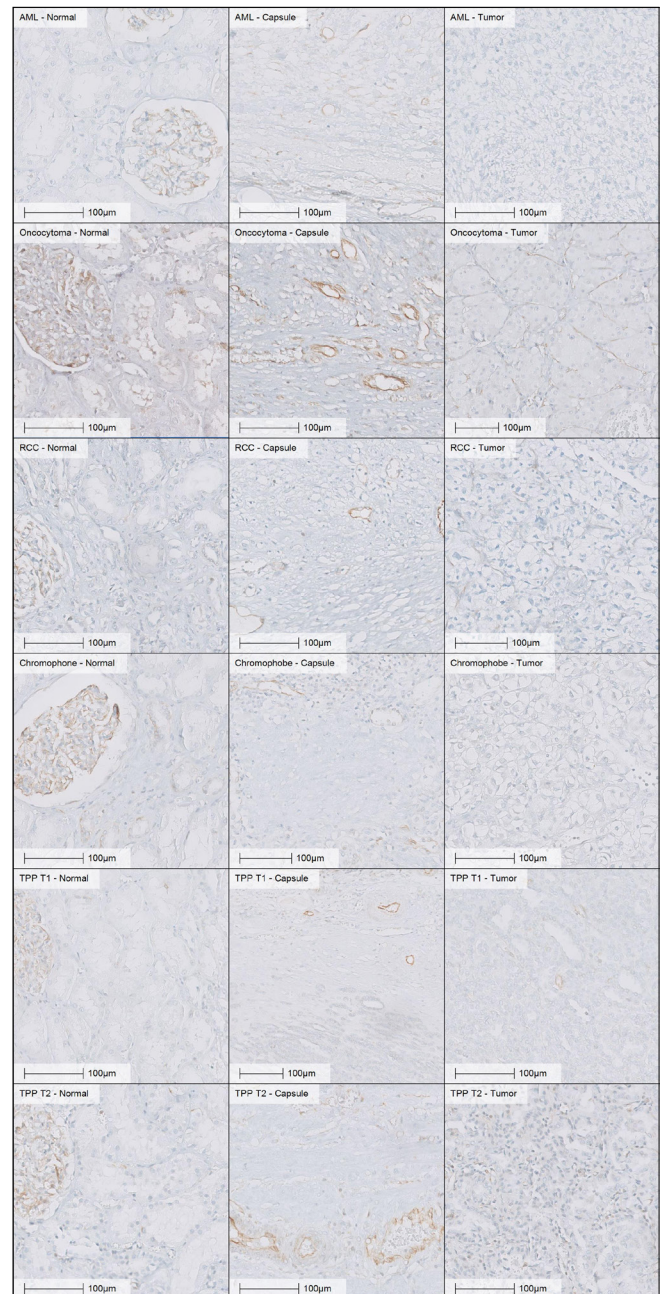
**FIGURE 2.**

CD34 immunostaining in adjacent normal, tumor capsular and tumor tissue in different types of renal neoplasms



**FIGURE 3.**

FSHR immunostaining in adjacent normal, tumor capsular and tumor tissue in different types of renal neoplasms



**Malignant versus benign renal cancers**

Immunostaining values for CD34 and FSHR stratified by cancer subtype and location (normal adjacent tissue, tumor capsule or tumor) are displayed in [Figure 4C-D](#) and [Table 1](#).

CD34 expression was highest in normal tissue, followed by tumor capsular and tumor tissues both for

malignant and benign neoplasms ( $P = 0.0301$  amongst benign and  $P < 0.0001$  for malignant lesions) but no relevant differences were found between expression in the tumor capsule and normal tissue of benign versus malignant diseases (both  $P > 0.2$ ). However, CD34 was slightly but statistically significantly more highly expressed in benign (5.69, IQR 3.5 to 7.3) versus malignant tumor tissues (4.92, IQR 1.7 to 7.1,  $P < 0.0001$ ).

TABLE 1.

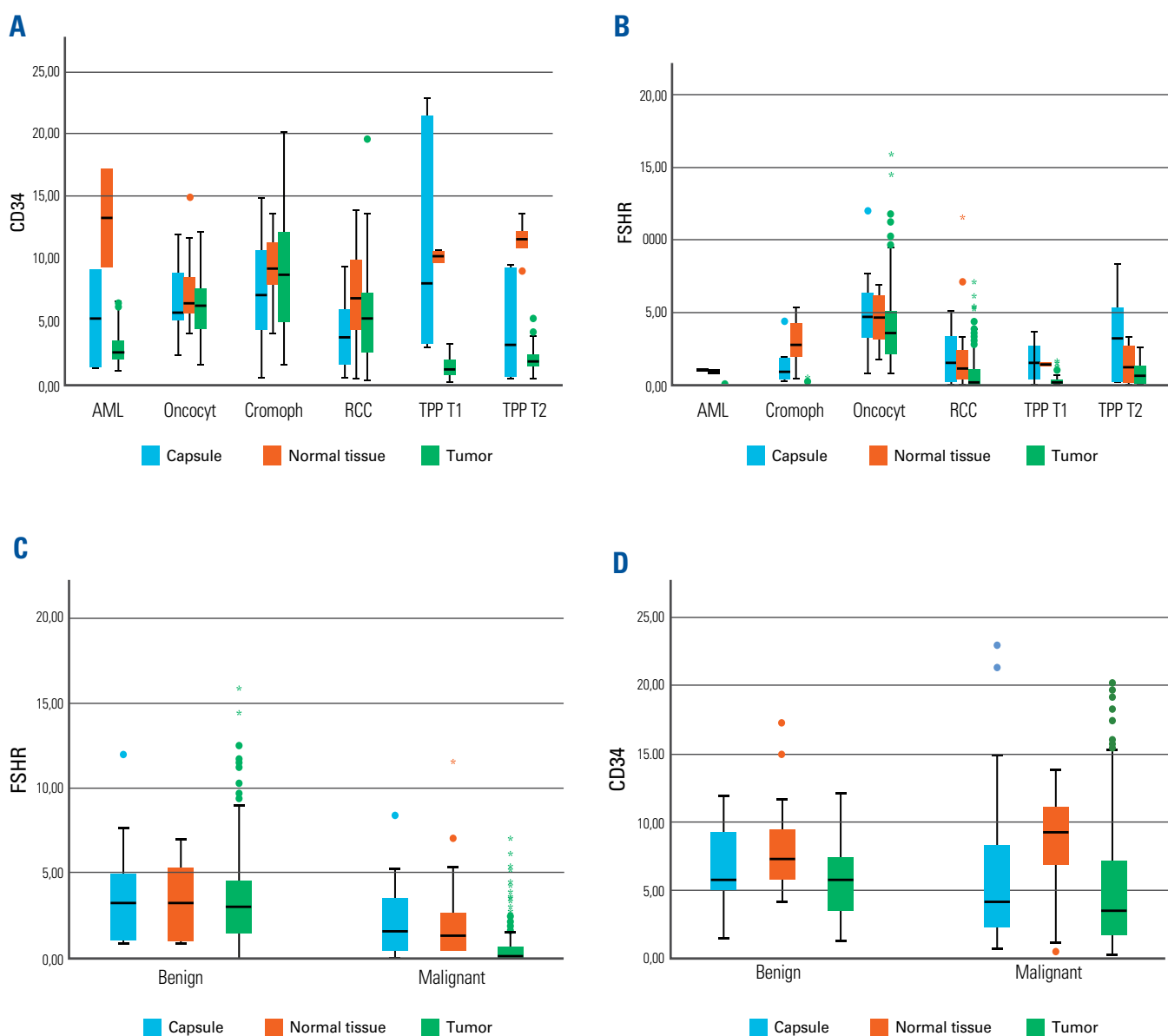
Immunostaining values of CD34 and FSHR stratified by tumor type and site

CD34 % staining (IQR)							
	All		ccRCC		Cromophobe Carcinoma		
Normal	8.58	(5.9–11.0)	6.98	(4.5–9.8)	9.84	(8.3–10.8)	
Capsule	6.12	(2.7–8.6)	3.97	(1.8–5.8)	7.53	(5.3–9.5)	
Tumor	5.10	(2.0–7.2)	5.42	(2.7–7.3)	8.72	(5.2–12.2)	
<i>P</i>	<b>&lt;0.0001</b>		<b>0.0399</b>		0.6131		
All			5.41	(2.63–7.42)	8.69	(5.3–12.2)	
<b>Benign</b>							
Normal							
Capsule							
Tumor							
<i>P</i>							
All							
<b>Chromophobe</b>							
Normal							
Capsule							
Tumor							
<i>P</i>					0.6131		
All							
FSHR % staining (IQR)							
	All		ccRCC		Cromophobe Carcinoma		
Normal	2.22	(0.7–2.7)	2.03	(0.5–2.3)	3.12	(2.6–3.7)	
Capsule	2.49	(2.7–8.6)	1.94	(0.2–3.2)	1.47	(0.4–1.7)	
Tumor	1.28	(0.03–1.8)	0.82	(0.01–1.1)	0.08	(0.02–0.1)	
<i>P</i>	<b>&lt;0.0001</b>		<b>0.0002</b>		<b>&lt;0.0001</b>		
All			0.98	(0.02–1.4)	0.32	(0.02–0.2)	
<b>Benign</b>							
Normal							
Capsule							
Tumor							
<i>P</i>							
All							
<b>Chromophobe</b>							
Normal							
Capsule							
Tumor							
<i>P</i>							
All							

	pRCC1		pRCC2		Oncocytoma		AML		P value
	10.24	(10.0–10.5)	11.49	(11.0–12.2)	7.57	(5.8–8.3)	13.33	(9.4–17.2)*	0.0196
	11.16	(3.8–18.9)	4.47	(1.2–8.0)	6.83	(5.3–8.8)	5.31	(1.4–9.2)*	0.1450
	1.45	(0.9–2.0)	2.09	(1.5–2.5)	6.27	(4.5–7.7)	3.05	(2.2–3.5)	<b>&lt;0.0001</b>
	<b>&lt;0.0001</b>		<b>0.0002</b>		<i>0.4914</i>		<i>0.0663</i>		
	2.33	(1.0–2.2)	2.96	(1.5–3.0)	6.43	(4.7–7.8)	3.89	(2.1–4.4)	<b>&lt;0.0001</b>
					<b>Malignant</b>				
		8.39	(5.9–9.4)				8.67	(6.9–11.0)	0.4274
		6.61	(5.1–9.0)				5.93	(2.3–8.1)	0.2275
		5.69	(3.5–7.3)				4.92	(1.7–7.1)	<b>&lt;0.0001</b>
		<b>0.0301</b>					<b>&lt;0.0001</b>		
		5.98	(3.7–7.7)				5.20	(1.8–7.6)	<b>&lt;0.0001</b>
					<b>Oncocytoma</b>				
		9.84	(8.3–10.8)				7.57	(5.8–8.3)	0.0678
		7.53	(5.3–9.5)				6.83	(5.3–8.8)	0.6160
		8.72	(5.2–12.2)				6.27	(4.5–7.7)	<b>0.0003</b>
					<i>0.4914</i>				
		8.69	(5.3–12.2)				6.43	(4.67–7.8)	<b>&lt;0.0001</b>
	pRCC1		pRCC2		Oncocytoma		AML		P value
	1.29	(1.3–1.3)	1.35	(2.2–2.5)	4.65	(3.8–5.7)	0.92	(0.8–1.1)	0.1120
	1.63	(0.5–2.5)	3.44	(0.8–5.0)	5.25	(3.3–6.3)	1.05	(1.0–1.1)	0.1400
	0.29	(0.0–0.3)	0.82	(0.2–1.3)	4.28	(2.2–5.1)	0.02	(0–0.01)	<b>&lt;0.0001</b>
	<b>0.0005</b>		<i>0.0691</i>		<b>&lt;0.0001</b>		<b>0.0059</b>		
	0.41	(0.06–0.43)	1.07	(0.18–1.6)	4.35	(2.2–5.2)	0.15	(0–0.02)	<b>&lt;0.0001</b>
					<b>Malignant</b>				
		3.41	(1.2–5.1)				1.99	(0.5–2.6)	0.1932
		4.32	(1.1–4.9)				2.05	(0.4–3.4)	0.0500
		3.50	(1.5–4.5)				0.61	(0.02–0.65)	<b>&lt;0.001</b>
		<i>0.7875</i>					<b>&lt;0.0001</b>		
		3.55	(1.35–4.8)				0.80	(0.03–1.072)	<b>&lt;0.001</b>
					<b>Oncocytoma</b>				
		3.12	(2.6–3.7)				4.65	(3.8–5.7)	0.4705
		1.47	(0.4–1.7)				5.25	(3.3–6.3)	<b>0.0268</b>
		0.08	(0.02–0.1)				4.28	(2.2–5.1)	<b>&lt;0.0001</b>
		<b>&lt;0.0001</b>					<b>&lt;0.0001</b>		
		0.32	(0.02–0.2)				4.35	(2.2–5.2)	<b>&lt;0.0001</b>

**FIGURE 4.**

CD34 and FSHR immunostaining in adjacent normal, tumor capsular and tumor tissue amongst different types of renal neoplasms



A. CD34 stratified per tumor subtype; B. FSHR stratified by tumor subtype; C. CD34 stratified by malignant versus benign tumor; D. FSHR stratified by malignant versus benign tumor; AML: angiomyolipoma; chromoph: chromophobe carcinoma; pRCC: papillary renal cell carcinoma; ccRCC: clear cell renal cell carcinoma.

FSHR was expressed similarly in normal, tumor capsular, and benign tumor tissues and no relevant differences with corresponding sites related to malignant tumors were noted (normal tissue  $P = 0.19$  and tumor capsule  $P = 0.05$ ). However, FSHR expression was significantly greater in benign (3.55, IQR 1.5 to 4.5) versus malignant tumor tissues (0.15, IQR 0.02 to 0.65,  $P < 0.0001$ ).

ROC curves are displayed in [Figure 5A](#). The highest AUC in differentiating malignant from benign tumors was for FSHR (AUC 0.805; 95% CI 0.771 to 0.837). The discriminating ability of FSHR alone was comparable to the use of the combination of FSHR and CD34 (AUC 0.805; 95% CI 0.770 to 0.837,  $P = 0.9920$ ) and superior to CD34 alone (AUC 0.630; 95% CI 0.589 to 0.669,  $P < 0.0001$ ).



### Oncocytoma versus chromophobe carcinoma

CD34 expression was overall not significantly different amongst different sites within oncocytomas and chromophobe subtypes (both  $P > 0.4$ ). Similarly, no significant staining differences were observed between tumor capsular and normal tissues of oncocytomas versus chromophobe carcinomas (both  $P > 0.05$ ). Nonetheless, CD34 was present at higher levels in chromophobe carcinoma (8.72; IQR 5.3 to 12.2) versus oncocytoma tumor tissues (6.27, IQR 4.5 to 7.8,  $P = 0.0003$ ).

FSHR was expressed differently in normal, capsular, and tumor tissues both for chromophobe carcinomas and oncocytomas (both  $P < 0.0001$ ). FSHR was significantly higher in capsular sections related to oncocytoma compared with chromophobe carcinoma (5.25, IQR 3.3 to 6.3 versus 1.47, IQR 0.4-1.7;  $P = 0.0268$ ) and even more markedly expressed in tumor tissue from oncocytoma (4.28, IQR 2.2 to 5.1) compared with chromophobe carcinoma, where the FSHR was almost not expressed (0.08, IQR 0.02 to 0.1;  $P < 0.0001$ ).

ROC curves are displayed in **Figure 5B**. FSHR expression in tumor tissues was able to accurately differentiate oncocytomas from chromophobe carcinomas (AUC 0.973; 95% CI 0.939 to 0.991). The discriminating ability of FSHR alone was comparable to the combination of FSHR and CD34 (AUC 0.973; 95% CI 0.939 to 0.991,  $P = 0.9875$ ) and superior to that of CD34 alone (AUC 0.666; 95% CI 0.595 to 0.731;  $P < 0.0001$ ).

### Capsular distance in cancerous tissue

The correlation amongst levels of staining in tumor tissues and distance from the capsule were overall weak (Spearman's coefficient CD34 -0.0644; FSHR-0.16322) and different amongst different cancer subtypes (**Supplementary Table S1**). Lowest and highest correlation for CD34 were with tpRCC2 (0.01529) and chromophobe carcinoma (0.18685), respectively and for FSHR with chromophobe carcinoma (0.01521) and AML (-0.349949), respectively.

## Discussion

In the current study, we assessed CD34 and FSHR expression in different renal cancer subtypes, including benign and malignant neoplasms and cancerous and non-cancerous surrounding tissues. To our knowledge, this is the first work to detail CD34 and FSHR expression in this context. Several findings of our work are of interest.

First, we found both markers can vary widely amongst different subtypes of renal cancers. This holds true especially for the expression of CD34 and FSHR in cancerous tissues, but differences amongst cancer subtypes in normal surrounding tissues and in the

capsule are less marked. A limited number of studies investigated immunostaining levels depending on kidney cancer histology for CD34[25,26], suggesting different levels of expression, and no studies assessed FSHR. Immunostaining differences need to be further explored to determine the possible roles of these molecules in different types of carcinogenetic pathways according to the corresponding cancer subtypes.

Second, within the same renal cancer subtype, CD34 and FSHR also vary significantly, depending on whether we analyzed the normal peri-tumoral tissue, the capsule, or the cancer. Some cancers, as for TPP1 and TPP2 for CD34, have markedly higher staining outside the cancerous areas, and others, like oncocytomas, have similar levels of expression throughout different sites. Indeed, patterns of expression of these molecules, whether they are more or less present towards the cancerous or non-cancerous tissues or whether they are more or less uniform throughout different sites, also mandate further assessment as they may help in recognizing different renal cancers and in clarifying different molecular carcinogenetic pathways.

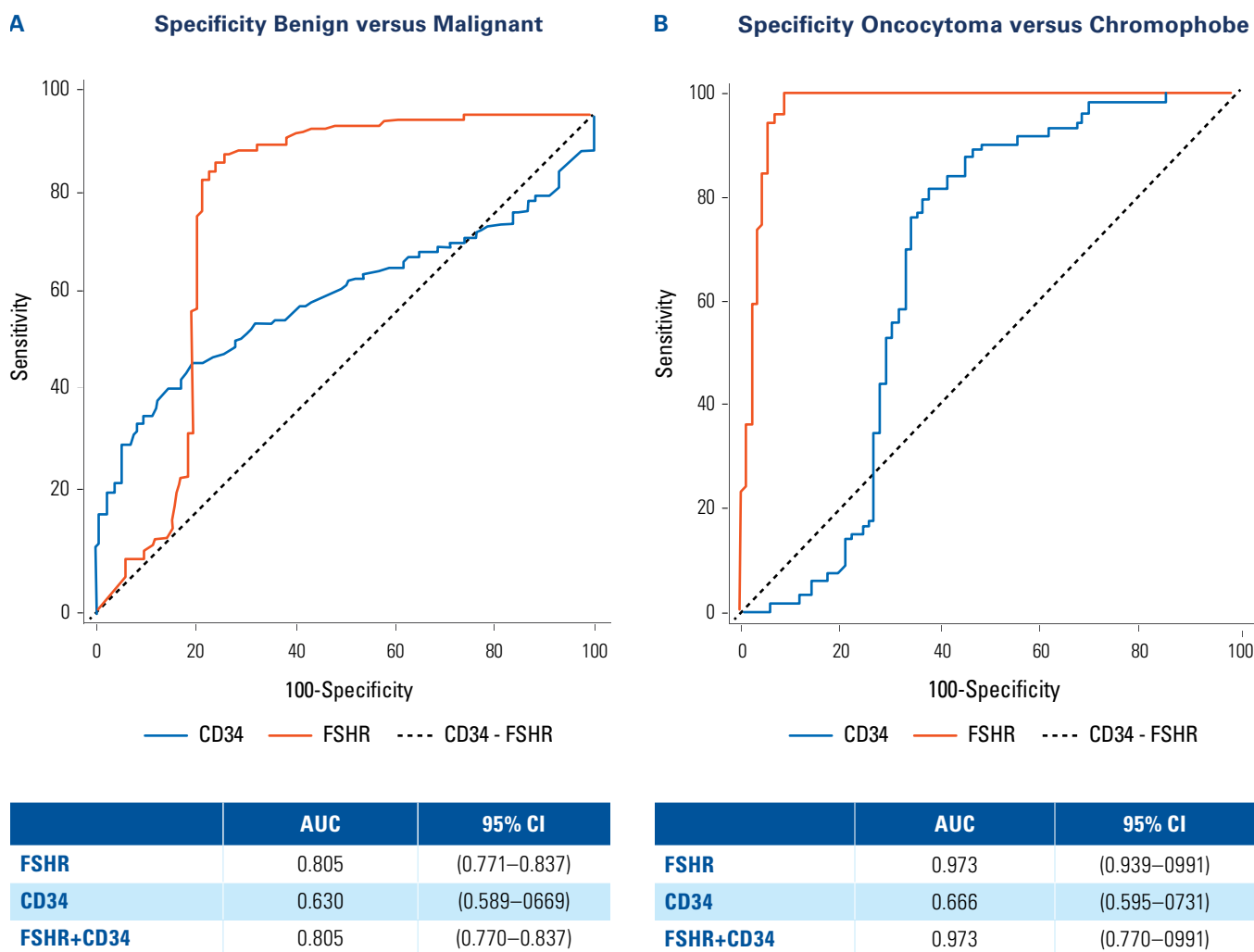
An increased staining at the level of the cancer surface may suggest increased angiogenesis and invasive and metastatic potential for cancer cells, through newly formed vessels deriving from FSHR pathway activation[27]. Similarly, previous authors suggested VEGF-mediated downregulation of CD34 adhesion molecule may constitute a tumor-mediated escape mechanism from immune surveillance[28].

In this context, it was interesting to note there were only weak correlations/changes in CD34 and FSHR expression depending on the depth within the cancerous tissues. Others detailed a shell type distribution of the FSHR receptor, reaching the highest level of expression at the border between normal and cancerous tissues and then gradually decreasing inside and outside the cancer. This finding was noted for all the 11 different cancers analyzed, except for renal cell carcinoma, where, as in our work, only mild differences between cancerous and non-cancerous tissues and overall weak correlation of FSHR and CD34 expression and distance from the capsule were highlighted[15]. Whether these findings may be related to different angiogenetic molecular pathways in kidney neoplasms and/or linked to the relatively high radiation and drug resistance of kidney neoplasms remains to be understood[29].

Third, CD34 and FSHR may help in differentiating benign and malignant renal cancers as, especially when looking at cancerous areas, they are both more expressed in benign tumors. Importantly, this difference, although being statistically significant, remains weak for CD34 and possibly not clinically meaningful. By contrast, the expression difference of FSHR between benign and



**FIGURE 5.**  
ROC analysis and respective AUC values to differentiate amongst subtype of kidney tumor



A. Benign versus malignant tumors; CD34 cut-off for malignant tumor  $\leq 2.6136\%$  - Youden index 0.2740; FSHR cut-off for oncocytoma identification  $\leq 1.6025\%$  - Youden index 0.6223. B. Oncocytoma versus chromophobe carcinoma; CD34 cut-off for oncocytoma identification  $\leq 9.2097\%$  - Youden index 0.3661; FSHR cut-off for oncocytoma identification  $> 0.5421\%$  - Youden index 0.9176.

malignant renal cancers is more pronounced. In fact, if used as a diagnostic test, FSHR has acceptable to excellent ability in discriminating between benign and malignant lesions. Not only is the FSHR discriminating ability superior to that of CD34 alone, but it does not significantly increase if used in combination with CD34.

Fourth, CD34 and FSHR may also be useful in distinguishing oncocytoma from chromophobe carcinoma. Again, while CD34 staining differs little between tumor types, FSHR is expressed at very low levels in chromophobe carcinoma and at a high level in oncocytoma. As such, FSHR has an outstanding discriminating ability in differentiating these 2 tumor types, with an AUC of 0.973 (95% CI 0.939 to 0.991).

Currently, relatively poor evidence is present for diagnostic biomarkers and for the ability of differentiating amongst different renal cancer subtypes overall. Several molecules have been tested in a diagnostic setting. However, even the most promising ones, including PAX2 and PAX8, vimentin, cytokeratine 7 and other subtypes, and c-kit, have a limited diagnostic ability and/or show relevant limitations such as negativizing in high-grade tumors, or not staining in some of the commonest renal malignancies[30]. Contrarily, a recent meta-analysis highlighted several promising molecules that may help to differentiate ChC from oncocytomas, warranting future comparisons with our results[24].

Several groups already showed FSHR expression in different cancerous tissues[15]. Nonetheless, FSHR

expression in renal neoplasms has been explored in only a few reports limited to renal cell carcinoma.

From a clinical perspective FSHR may have important implications in a diagnostic setting. Cancer misclassification on biopsy specimens is not infrequent overall and as many as 1 in 3 oncocytomas detected on biopsy are found to be chromophobe carcinoma on examination of the surgical specimen[22]. Considering the global increase in the use of renal biopsy and the diagnostic shift towards small renal masses[18,31], the ability of FSHR to rule out malignant disease and chromophobe carcinomas urgently requires further investigation. If confirmed, FSHR use may have a relevant impact on clinical decision-making.

Another potential application may be represented by *in vivo* diagnostic imaging. Radu et al. proved intravenous accessibility of the FSHR using gold-labeled-antibodies in prostate cancer xenograft mouse models. Furthermore, distribution in normal organs was low[15]. Recently, Ingels and colleagues showed *in vivo* ultrasound with targeted FSHR microbubbles may correlate with sunitinib treatment response in mouse renal cell carcinoma[32]. If confirmed in patients, FSHR-based imaging could be used to identify renal tumor subtype, which would dictate which lesions require further investigation and possibly intervention.

In a prognostic setting, the value of FSHR remains unknown. Given our initial findings on its ability to discriminate between malignant and benign diseases and the findings of other studies detailing its ability in predicting treatment response[29], it is our intent to clarify their prognostic abilities within malignant diseases in the near future. Similarly, previous reports found possible prognostic value for CD34, depending on its immunostaining pattern for renal cell carcinoma[8].

From a research perspective, further efforts should be made to elucidate possible roles of FSHR and CD34 in kidney cancer pathways. CD34 may play a role in cancer immune escape but its role overall remains largely unknown[28]. On the contrary, amongst its several functions, the FSH/FSHR axis has been shown to increase angiogenesis through the HIF-1 and VEGF pathway[33], with FSHR overexpression promoting

VEGF/VEGF-receptor binding, and, thus, angiogenesis. Furthermore, the pathway also promotes activation of G proteins in endothelial cells with activate VEGF receptor in the absence of VEGF, possibly inducing proliferation and migration independent of VEGF[34,35]. Not surprisingly, some authors have speculated that blocking FSH-receptor may represent a valid antitumor strategy, inhibiting angiogenesis. Furthermore, FSHR is expressed on the luminal surface of endothelial cells, thus being an ideal target for ligands to induce peritumoral vascular infarction[36].

In this sense, our work also clarifies FSHR may have a limited interest as a direct binding site for therapeutic drugs. Others have hypothesized FSHR may represent an important target because its expression is higher in cancerous than in normal Sertoli and granulosa cells[15]. In the context of kidney cancer, we found FSHR is more highly expressed in benign tumors and associated normal tissue than in malignant tumors and associated normal tissue. Nonetheless, we sampled only normal tissue surrounding the cancer, possibly including areas where molecular alterations may be more reflective of tumor microenvironment than unaltered normal tissues, which calls for further analysis.

Our work has some limitations. We included a relatively small number of cases and, as a consequence, we did not perform multivariable analysis adjusting for patient features and/or investigating possible roles in patient prognosis. Nonetheless, our aim was to perform a preliminary analysis. On the basis of our present results, we are in the process of increasing the number of patients to confirm our preliminary findings.

## Conclusion

From our preliminary analysis of CD34 and FSHR in different subtypes of renal neoplasms, we found they are differently expressed in renal tumors and/or surrounding tissues depending on the Ca histology. FSHR expression alone may be a useful tool to differentiate amongst benign and malignant subtypes and chromophobe carcinomas and oncocytomas. Larger studies are needed to confirm our findings and to evaluate their potential applications.

## References

- Folkman J, Watson K, Ingber D, Hanahan D. Induction of angiogenesis during the transition from hyperplasia to neoplasia. *Nature*.1989;339:58–61. <https://doi.org/10.1038/339058a0>
- Vieira SC, Silva BB, Pinto GA, Vassallo J, Moraes NG, Santana JOI, et al. CD34 as a marker for evaluating angiogenesis in cervical cancer. *Pathol Pract*.2005;201:313–318. <https://doi.org/10.1016/j.prp.2005.01.010>
- Fiedler U, Christian S, Koidl S, Kerjaschki D, Emmett MS, Bates DO, et al. The sialomucin CD34 is a marker of lymphatic endothelial cells in human tumors. *Am J Pathol*.2006;168:1045–1053. <https://doi.org/10.2353/ajpath.2006.050554>
- Tenderenda M, Rutkowski P, Jesionek-Kupnicka D, Kubiak R. Expression of CD34 in gastric cancer and its correlation with histology, stage, proliferation activity, p53 expression and apoptotic index. *Pathol Oncol Res*.2001;7:129–134. <https://doi.org/10.1007/BF03032579>
- Coston WMP, Loera S, Lau SK, Ishizawa S, Jiang Z, Wu C-L, et al. Distinction of hepatocellular carcinoma from benign hepatic mimickers using glypican-3 and CD34 immunohistochemistry. *Am J Surg Pathol*.2008;32:433–444. <https://doi.org/10.1097/PAS.0b013e318158142f>
- Foroozan M, Roudi R, Abolhasani M, Gheyntanchi E, Mehrazma M. Clinical significance of endothelial cell marker CD34 and mast cell marker CD117 in prostate adenocarcinoma. *Pathol Res Pract*.2017;213:612–618. <https://doi.org/10.1016/j.prp.2017.04.027>
- Nassif AE, Filho RT. Immunohistochemistry expression of tumor markers CD34 and P27 as a prognostic factor of clinically localized prostate adenocarcinoma after radical prostatectomy. *Rev Col Bras Cir*.2010;37:338–344. <https://doi.org/10.1590/s0100-69912010000500006>
- López JI, Erramuzpe A, Guarch R, Cortés JM, Pulido R, Llarrea R, et al. CD34 immunostaining enhances a distinct pattern of intratumor angiogenesis with prognostic implications in clear cell renal cell carcinoma. *APMIS*.2017;125:128–133. <https://doi.org/10.1111/apm.12649>
- Ajili F, Kacem M, Tounsi H, Darouiche A, Enayfer E, Chebi M, et al. Prognostic impact of angiogenesis in nonmuscle invasive bladder cancer as defined by Microvessel density after immunohistochemical staining for CD34. *Ultrastruct Pathol*.2012;36:336–342. <https://doi.org/10.3109/01913123.2012.672847>
- Sprengel R, Braun T, Nikolics K, Segaloff DL, Seeburg PH. The testicular receptor for follicle stimulating hormone: structure and functional expression of cloned cDNA. *Mol Endocrinol*.1990;4:525–530. <https://doi.org/10.1210/mend-4-4-525>
- Papadimitriou K, Kountourakis P, Kottorou AE, Antonacopoulou AG, Rolfo C, Peeters M, et al. Follicle-stimulating hormone receptor (FSHR): a promising tool in oncology? *Mol Diagnosis Ther*.2016;20:523–530. <https://doi.org/10.1007/s40291-016-0218-z>
- Zhang Z, Jia L, Feng Y, Zheng W. Overexpression of follicle-stimulating hormone receptor facilitates the development of ovarian epithelial cancer. *Cancer Lett*.2009;278:56–64. <https://doi.org/10.1016/j.canlet.2008.12.024>
- Mariani S, Salvatori L, Basciani S, Arizzi M, Franco G, Petrangeli E, et al. Expression and cellular localization of follicle-stimulating hormone receptor in normal human prostate, benign prostatic hyperplasia and prostate cancer. *J Urol*.2006;175:2072–2077. [https://doi.org/10.1016/S0022-5347\(06\)00273-4](https://doi.org/10.1016/S0022-5347(06)00273-4)
- Ben-Josef E, Yang SY, Ji TH, Bidart JM, Garde SV, Chopra DP, et al. Hormone-refractory prostate cancer cells express functional follicle-stimulating hormone receptor (FSHR). *J Urol*.1999;161:970–976. [https://doi.org/10.1016/S0022-5347\(01\)61831-7](https://doi.org/10.1016/S0022-5347(01)61831-7)
- Radu A, Pichon C, Camparo P, Antoine M, Allory Y, Couvelard A, et al. Expression of follicle-stimulating hormone receptor in tumor blood vessels. *N Engl J Med*.2010 Oct 21;363(17):1621-1630. doi: 10.1056/NEJMoa1001283.
- Siraj A, Desestret V, Antoine M, Fromont G, Huerre M, Sanson M, et al. Expression of follicle-stimulating hormone receptor by the vascular endothelium in tumor metastases. *BMC Cancer*.2013;13:246. <https://doi.org/10.1186/1471-2407-13-246>
- Siegel RL, Miller KD, Jemal A. Cancer statistics, 2020. *CA Cancer J Clin*.2020;70:7–30. <https://doi.org/10.3322/caac.21590>
- Marra G, Oderda M, Allasia M, Munegato S, Joniau S, Gontero P. A review on the management of small renal masses: active surveillance versus surgery. *Anticancer Agents Med Chem*.2018;18:940–950. <https://doi.org/10.2174/1871520617666171113123443>
- Rosenkrantz AB, Hindman N, Fitzgerald EF, Niver BE, Melamed J, Babb JS. MRI features of renal oncocytoma and chromophobe renal cell carcinoma. *Am J Roentgenol*.2010;195(6):W421-7. doi: 10.2214/AJR.10.4718
- Hindman N, Ngo L, Genega EM, Melamed J, Wei J, Braza JM, et al. Angiomyolipoma with minimal fat: can it be differentiated from clear cell renal cell carcinoma by using standard MR techniques? *Radiology*.2012;265:468–477. <https://doi.org/10.1148/radiol.12112087>
- Richard PO, Jewett MAS, Bhatt JR, Evans AJ, Timilsina N, Finelli A. Active surveillance for renal neoplasms with oncocytic features is safe. *J Urol*.2016;195(3):581-586. doi: 10.1016/j.juro.2015.09.067. Epub 2015 Sep 24.
- Patel HD, Druskin SC, Rowe SP, Pierorazio PM, Gorin MA, Allaf ME. Surgical histopathology for suspected oncocytoma on renal mass biopsy: a systematic review and meta-analysis. *BJU Int*.2017;119:661–666. doi: 10.1111/bju.13763. Epub 2017 Feb 27.
- Ljungberg B, Albiges L, Abu-Ghanem Y, Bensalah K, Dabestani S, Fernández-Pello S, et al. European Association of Urology guidelines on renal cell carcinoma: the 2019 update. *Eur Urol*.2019;75:799–810. <https://doi.org/10.1016/j.eururo.2019.02.011>

24. Ng KL, Morais C, Bernard A, Saunders N, Samaratunga H, Gobe G, et al. A systematic review and meta-analysis of immunohistochemical biomarkers that differentiate chromophobe renal cell carcinoma from renal oncocytoma. *J Clin Pathol*.2016;69:661–671. <https://doi.org/10.1136/jclinpath-2015-203585>
25. Dekel Y, Koren R, Kugel V, Livne PM, Gal R. Significance of angiogenesis and microvascular invasion in renal cell carcinoma. *Pathol Oncol Res*.2002;8:129–132. <https://doi.org/10.1007/BF03033722>
26. Yilmazer D, Han Ü, Önal B. A comparison of the vascular density of VEGF expression with microvascular density determined with CD34 and CD31 staining and conventional prognostic markers in renal cell carcinoma. *Int Urol Nephrol*.2007;39:691–698. <https://doi.org/10.1007/s11255-006-9123-4>
27. Fox SB, Gatter KC, Bicknell R, Going JJ, Stanton P, Cooke TG, et al. Relationship of endothelial cell proliferation to tumor vascularity in human breast cancer. *Cancer Res*.1993;53(18):4161-4163.
28. Hellwig SMM, Damen CA, Van Adrichem NPH, Blijham GH, Groenewegen G, Griffioen AW. Endothelial CD34 is suppressed in human malignancies: role of angiogenic factors. *Cancer Lett*.1997;120:203–211. [https://doi.org/10.1016/S0304-3835\(97\)00310-8](https://doi.org/10.1016/S0304-3835(97)00310-8)
29. Siraj MA, Pichon C, Radu A, Ghinea N. Endothelial follicle stimulating hormone receptor in primary kidney cancer correlates with subsequent response to sunitinib. *J Cell Mol Med*.2012;6:2010–2016. <https://doi.org/10.1111/j.1582-4934.2011.01495.x>
30. Farber NJ, Kim CJ, Modi PK, Hon JD, Sadimin ET, Singer EA. Renal cell carcinoma: the search for a reliable biomarker. *Transl Cancer Res*.2017;6:620–632. <https://doi.org/10.21037/tcr.2017.05.19>
31. Perera M, Papa N, Ischia J, Christidis D, Bolton D, Lawrentschuk N, et al. Trends in percutaneous renal biopsy: the evolving diagnostic pathway for the small renal mass. *Urol Ann*.2018;10(3):237-239. <https://doi.org/10.4103/0974-7796.236516>
32. Ingels A, Leguerney I, Cournède PH, Irani J, Ferlicot S, Sébrié C, et al. Ultrasound molecular imaging of renal cell carcinoma: VEGFR targeted therapy monitored with VEGFR1 and FSHR targeted microbubbles. *Sci Rep*.2020;10:1–8. <https://doi.org/10.1038/s41598-020-64433-2>
33. Alam H, Weck J, Maizels E, Park Y, Lee EJ, Ashcroft M, et al. Role of the phosphatidylinositol-3-Kinase and extracellular regulated kinase pathways in the induction of hypoxia-inducible factor (HIF)-1 activity and the HIF-1 target vascular endothelial growth factor in ovarian granulosa cells in response to follicle-stimulating hormone. *Endocrinology*.2009;150(2):915-928. [doi.org/10.1210/en.2008-0850](https://doi.org/10.1210/en.2008-0850)
34. Castro-Fernández C, Maya-Núñez G, Méndez JP. Regulation of follicle-stimulating and luteinizing hormone receptor signaling by “regulator of G protein signaling” proteins. *Endocrine* 2004;25:49–54. <https://doi.org/10.1385/ENDO.25:1:49>
35. Zeng H, Zhao D, Yang S, Datta K, Mukhopadhyay D. Heterotrimeric  $G\alpha_q/G\alpha_{11}$  proteins function upstream of vascular endothelial growth factor (VEGF) receptor-2 (KDR) phosphorylation in vascular permeability factor/VEGF signaling. *J Biol Chem*.2003;278:20738–20745. <https://doi.org/10.1074/jbc.M209712200>
36. Ghinea N. Vascular endothelial FSH receptor, a target of interest for cancer therapy. *Endocrinology*.2018;159:3268–3274. <https://doi.org/10.1210/en.2018-00466>

### SUPPLEMENTARY TABLE S1.

Spearman’s coefficient for correlation amongst levels of staining in tumor tissue and distance from the tumor capsule overall and amongst different tumor subtypes

Kidney Cancer Subtype	Spearman’s Coefficient	
	CD34	FSHR
All	<b>-0.0644</b>	<b>-0.16322</b>
AML	<u>0.03701</u>	<b>-0.34994</b>
Chromophobe carcinoma	<u>0.18685</u>	<u>0.01521</u>
Oncocytoma	<b>-0.16441</b>	<u>0.17977</u>
Clear cell renal cell carcinoma	<b>-0.09991</b>	<b>-0.19721</b>
Papillary renal cell carcinoma type 1	<b>-0.01529</b>	<u>0.23871</u>
Papillary renal cell carcinoma type 2	<b>-0.21508</b>	<u>0.11991</u>

Negative correlation: bold; positive correlation: underscored.