

# Pelvic Fracture Urethral Injury in Females

Pankaj M. Joshi,<sup>✉1</sup> Marco Bandini,<sup>1,2,3</sup> Christian Yepes,<sup>1</sup> Shreyas Bhadranavar,<sup>1</sup> Vipin Sharma,<sup>1</sup> Sandeep Bafna,<sup>1</sup> Sanjay B. Kulkarni<sup>1</sup>

<sup>1</sup>Kulkarni Reconstructive Urology Center, Pune, India <sup>2</sup>Unit of Urology, Urological Research Institute (URI), IRCCS Ospedale San Raffaele, Vita-Salute San Raffaele University, Milan, Italy <sup>3</sup>Centro Chirurgico Toscano, Arezzo, Italy

P.J., M.B., and C.Y. contributed equally to the manuscript

## Abstract

**Background** Pelvic fracture urethral injuries (PFUI) in females are very rare. The available literature on the management of this condition is scarce and not clear, mainly because of limited experience among reconstructive surgeons. We present our experience of management of these complex urethral injuries in female patients.

**Materials and Methods** We collected data, retrospectively and prospectively for 22 female patients referred to our center for PFUI repair between 1995 and 2021. During the clinical assessment of these complex injuries, following our internal institutional protocol, all patients underwent pelvic MRI (bladder and urethra are filled with saline solution and jelly to enhance the urethral lumen and the level of the distraction) before anastomotic urethroplasty.

**Results** PFUI compromised the mid urethra in 10 patients (45.5%). A transabdominal approach was used in 8 patients (80%), and urethra-vaginal fistula repair was undertaken in 6 patients (60%). After a median follow-up of 36 months, only 1 patient with proximal PFUI required a surgical revision without compromising urinary continence.

**Conclusions** The most common site of urethral involvement in pelvic fracture is mid urethral, which is owing to avulsion. Urethra-vaginal fistula should be suspected. Treatment consists in anastomotic urethroplasty, mainly through the abdominal approach.

## Introduction

Urethral injury in females with pelvic fractures is very rare<sup>[1–8]</sup>. The literature on the management of female urethral injuries is sparse and not consistent, largely because of limited experience worldwide. Further, patients include a wide spectrum from young girls to adult women, and so the referral may be to a pediatric urologist, a gynecologist, or a urologist.

The earliest report of such injuries was by Perry and Hussmann in 1992<sup>[5]</sup>. Injuries reported before this were longitudinal injuries, which may go unnoticed. The injuries we see in practice are usually avulsion injuries.

The Kulkarni Reconstructive Urology Center is a unique center with referrals from all over the world. Over last 2 decades we have treated 22 patients with pelvic fracture urethral injury (PFUI) and have acquired substantial experience. We believe these injuries should be classified differently in terms of age, with different management algorithms for prepubertal girls compared with adult females.

### Key Words

Female urethroplasty, pelvic fracture urethral injury, fistula, urethra, stricture

### Competing Interests

None declared.  
Patient Consent: Obtained for clinical images.

### Article Information

Received on October 6, 2021  
Accepted on January 5, 2022  
This article has been peer reviewed.  
Soc Int Urol J. 2022;3(2):77–86  
DOI: 10.48083/MBXR6354

We present our experience of management of female pelvic fracture urethral injuries, and we note that many of our findings have been published in reports on complex urethral injuries[9–11].

## Materials and Methods

We retrospectively and prospectively collected data on girls and women referred to our center for PFUI repair between 1995 and 2021. A detailed history was obtained, and patients were examined in the outpatient clinic. We obtained an ultrasound of the abdomen. Additionally, we annotated the position of suprapubic catheter and any previous scars on the abdomen, and we performed a local examination of the vulva. The female urethra is about 4 cm in length, and even smaller in young women and girls. Retrograde urethrogram and voiding cystourethrogram were considered critical for assessment of the urethral injury, and all patients received pelvic MRI, in which the bladder and urethra were filled with saline solution and jelly to enhance the lumen and the level of the urethral distraction (**Figures 1 and 2**)[12].

All patients proceeded to surgery within 1 day of coming to the hospital. Patients were admitted and received a single dose of preoperative antibiotics. Intraoperatively, we used the dorsal lithotomy position. Preoperative endoscopy was a critical part of evaluation, and the urethra was best visualized with a 0-degree endoscope. The best instrument for this proved to be the 7 Fr mini nephroscope or a 4.5 Fr ureteroscope, which was passed retrograde from the meatus to assess the distal urethra.

Urethrovaginal fistula should be suspected in every female patient with PFUI, and we found a urethrovaginal fistula in most of our patients. If possible, a guide wire was passed through the urethra into the bladder with the outside end brought out through the introitus. Subsequently, we performed a vaginoscopy, which usually showed a normal vagina with visualization of the cervix (**Figure 3**), a post-traumatic transverse vaginal septum preventing visualization of the cervix, or stenosis of the vagina at the site of trauma.

The next step was to perform endoscopy from the suprapubic catheter tract to visualize the bladder, the bladder neck, and the urethra proximal to the site of injury.

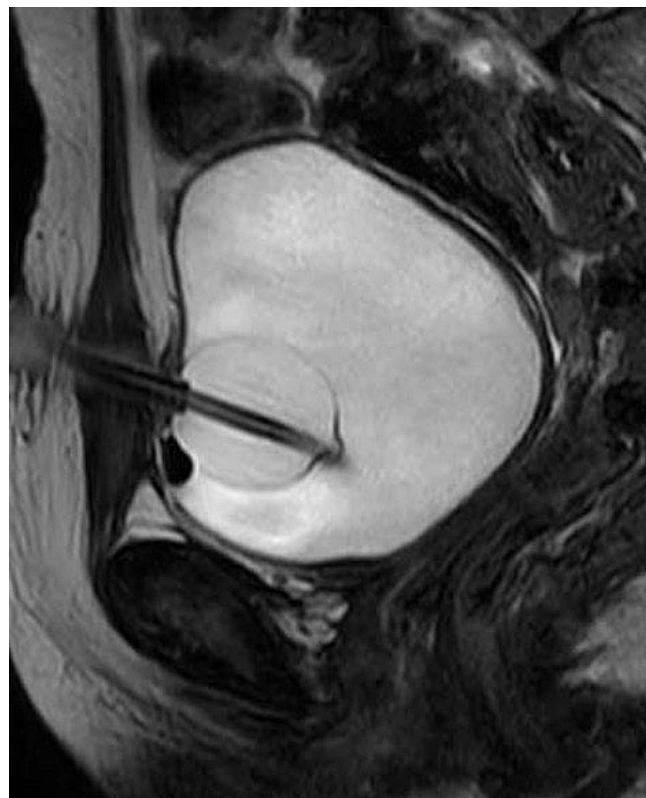
We typically saw urethral avulsion at the bladder neck, in the proximal urethra, or in the mid urethra. Some patients also exhibited meatal stenosis and/or accompanying urethrovaginal fistula and/or vaginal stenosis.

## Approach

The approach in prepubertal girls was always abdominal (**Figure 4**). In adult women, a vaginal approach was possible in some cases.

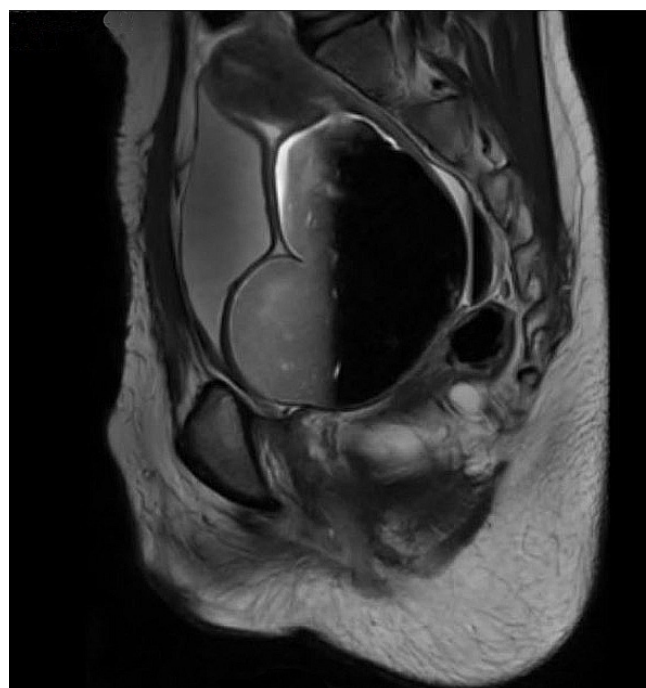
**FIGURE 1.**

MRI in female patient with pelvic fracture urethral injury



**FIGURE 2.**

MRI showing grossly dilated vagina and hematocolpos in a patient with prior repair of pelvic fracture urethral injury



### Transection at bladder neck

Injury at the bladder neck can result in transection of the bladder neck. When suprapubic endoscopy was performed in these cases, we could usually see a dimple that suggested the position of the bladder neck. Identification of the ureteric orifices and trigone also helped to locate the position of transected bladder neck.

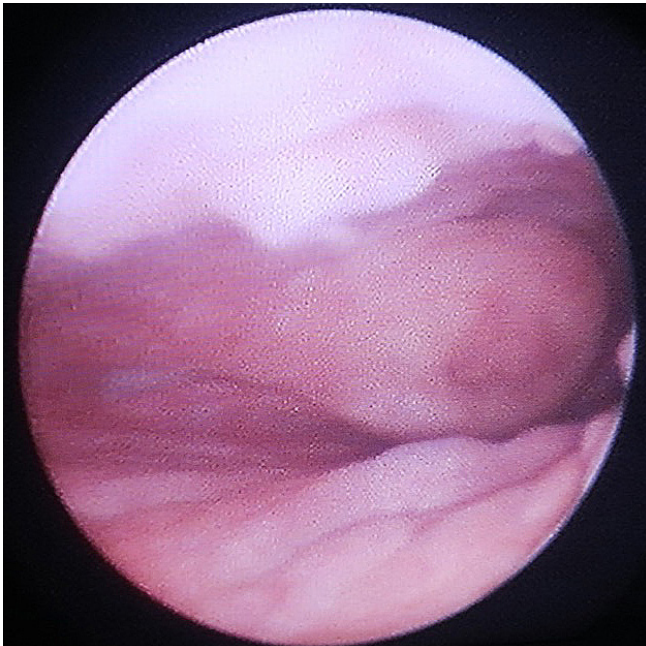
Surgical repair was performed through a lower abdominal incision. The extraperitoneal space was

entered and the bladder was released from its anterior attachments. A posterior and superior pubectomy was then performed (Figure 5). Scar tissue at the site of injury was excised. The urethra distal to the injury was incised over a dilator passed through the urethra from the meatus (Figure 6).

A 12 Fr mini nephroscope was passed through the suprapubic catheter site to guide the incision of the bladder. The anastomosis between the bladder neck and the

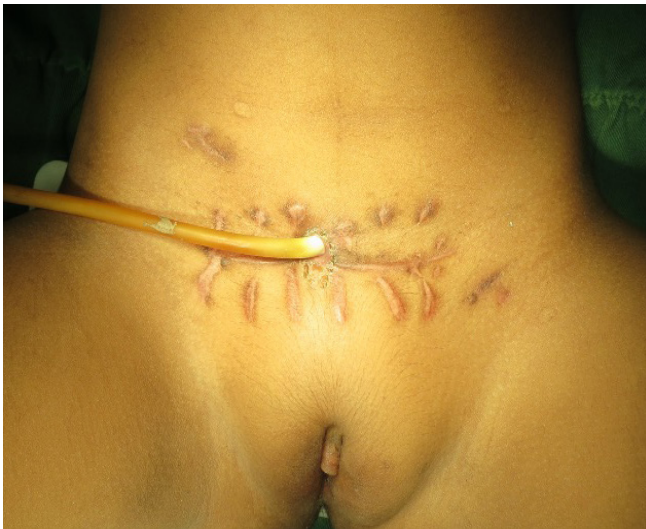**FIGURE 3.**

Vaginoscopy demonstrating cervix



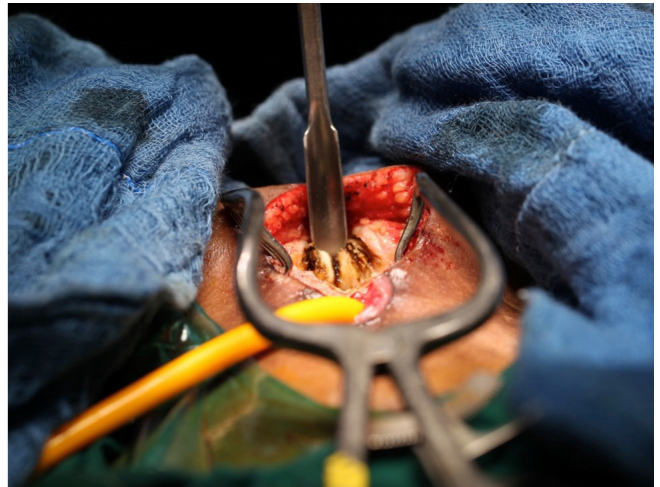
**FIGURE 4.**

Clinical picture of a girl after surgical revision of a pelvic fracture urethral injury



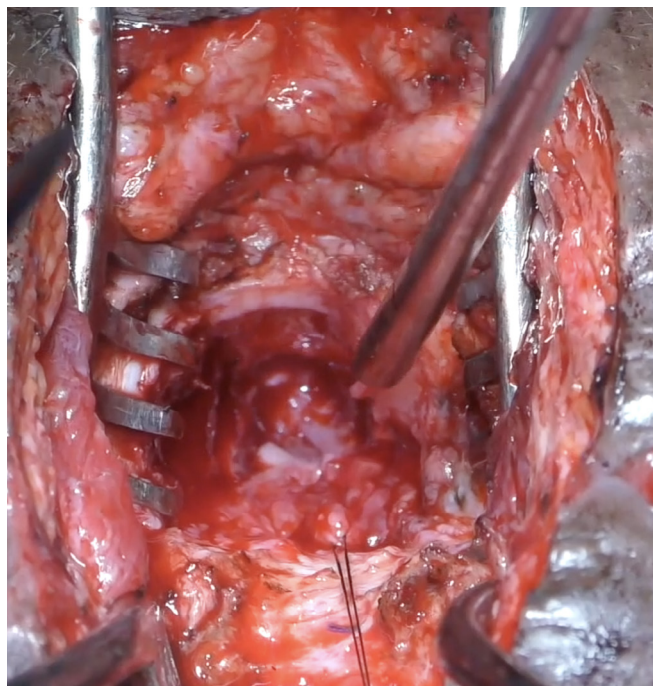
**FIGURE 5.**

Abdominal approach with posterior and superior pubectomy



**FIGURE 6.**

Abdominal approach with posterior and superior pubectomy



urethra was performed with six 5-0 polydioxone sutures. The posterior sutures were tied down (**Figure 7**) before passing a 14Fr silicon catheter across the anastomosis and tying down the anterior sutures. The omentum was mobilized and transposed onto the anastomosis. A drain was not usually required.

### Transection at proximal urethra

In cases with a proximal urethral injury a short length of intact urethra remained attached to the bladder. The surgical steps were the same as for a bladder neck injury, except that the anastomosis was performed between the 2 urethral ends. This was more challenging than bladder neck repair, as there is very narrow space to work in the female pelvis.

### Transection at mid urethra

The mid urethra was the commonest site of female PFUI. This type of injury is almost always associated with a urethrovaginal fistula, which can be missed (**Figure 8**). In these cases, transection of the mid urethra allows the distal urethra to connect to the anterior vaginal wall to form a fistula.

Intraoperative endoscopy, preferably with a 7 Fr or 12 Fr mini nephroscope, depending on the age of the patient, was more important in these cases. Endoscopy through the meatus into the distal urethra showed the

urethrovaginal fistula. A guide wire was passed through the fistula and back through the vagina. A confirmatory vaginoscopy was performed.

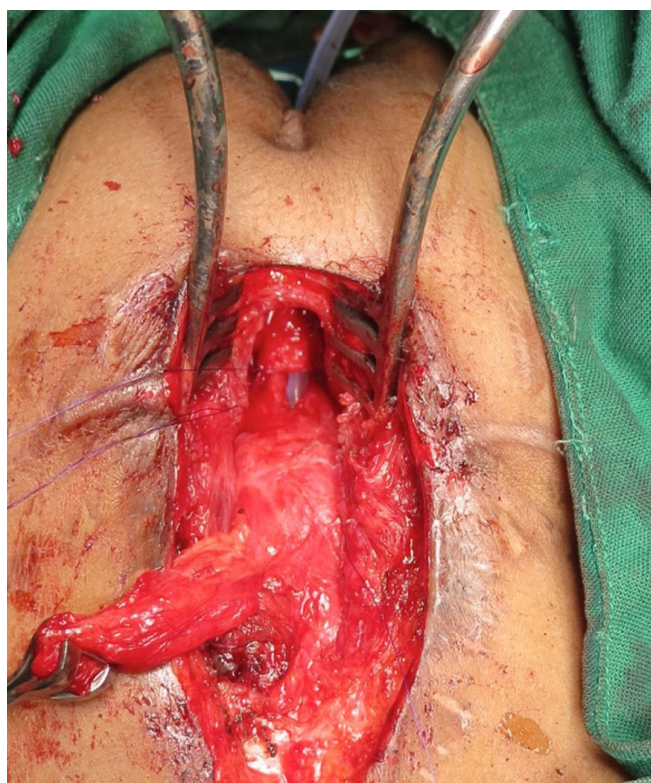
The surgical steps were similar to the previously described procedure but more challenging. A more extensive posterior and superior pubectomy was necessary to expose healthy edges of the proximal and distal urethra. The distal urethra was opened, and the previously inserted guide wire was pulled through the abdominal wound. The vaginal fistula was then clearly visible. The edges were freshened, and the fistula closed with interrupted polydioxone sutures. A long stay suture was placed and used to tuck the omentum between the urethral anastomosis and the anterior vaginal wall to create an intervening layer.

### Transection at meatus

Rarely, the injury was observed at the level of meatus (**Figure 9**), and this was usually associated with a vaginal injury. The meatus became hypospadiac. The vaginal injury healed with scarring leading to vaginal outlet stenosis. These patients voided through the vagina, where urine accumulated, and the patients presented with intermittent incontinence. The diagnosis was confirmed by vaginoscopy with small caliber endoscope. These patients needed to be treated with vaginotomy.

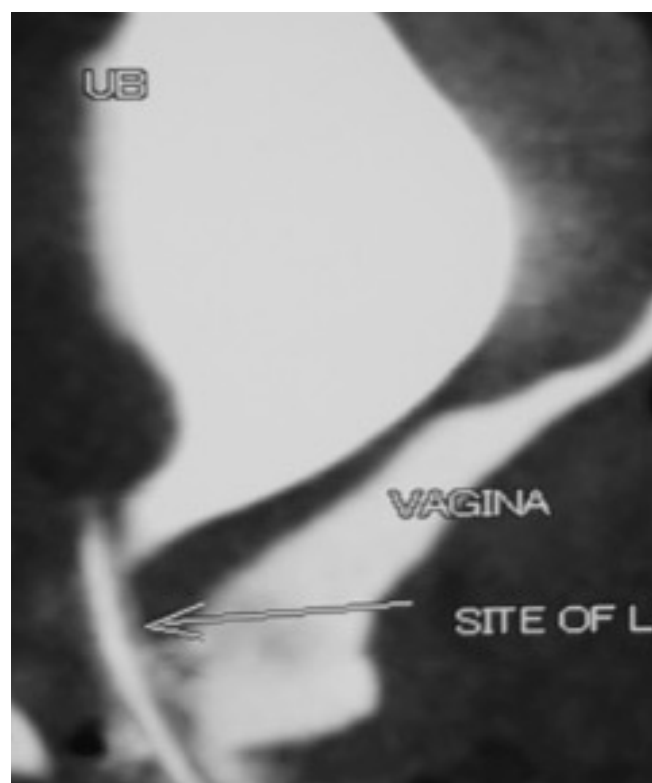
**FIGURE 7.**

Anastomosis



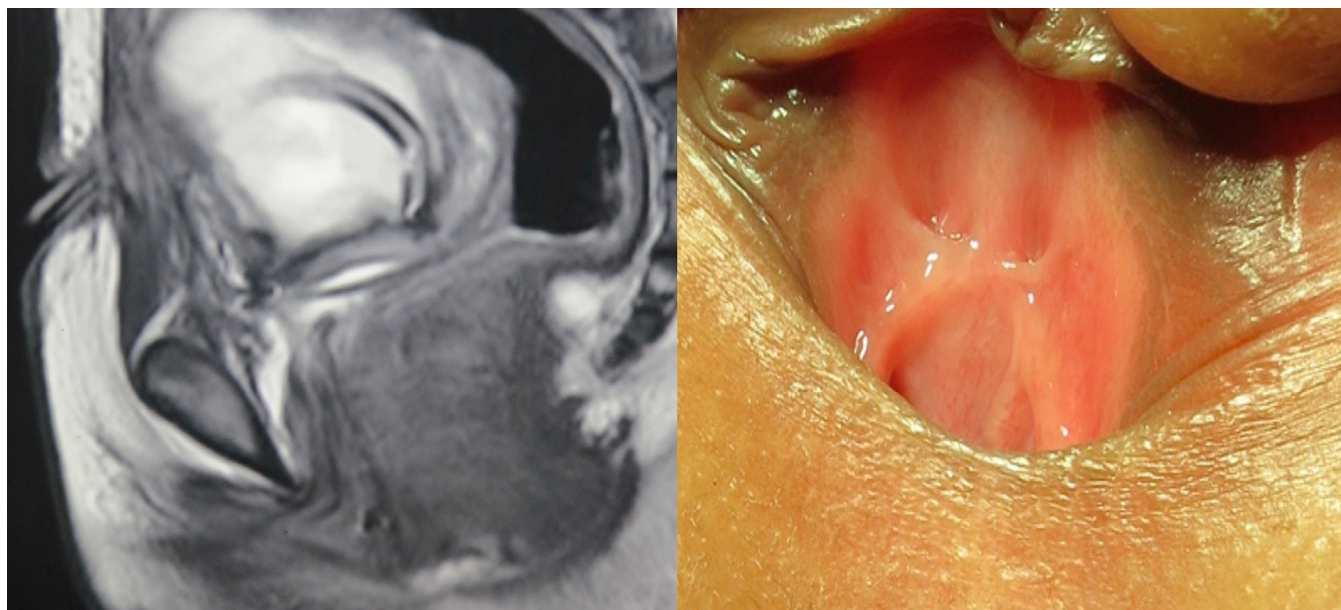
**FIGURE 8.**

Urethrovaginal fistula seen on CT



**FIGURE 9.**

## Distal urethral injury



Vaginal examination (which was difficult in pediatric patients because of narrow introitus) often revealed an almost bone-like scar on the posterior vaginal wall. Older patients sometimes needed a vaginal pull-through surgery, involving mobilization of the healthy edge of vagina down to be sutured to the introitus.

**Urethral lengthening**

In cases of meatal injury where treatment with meatotomy would result in a hypospadiac urethra and intravaginal voiding, we usually recommend a urethral lengthening procedure. This can be done with a pedicled inner labial skin flap which is sutured to the urethra. We performed this in 1 patient, who was satisfied with the result.

**Vaginal injury**

As stated earlier, urethrovaginal fistula was commonly seen in mid-urethral injuries.

Occasionally, the vagina was also transected. Resultant scarring sometimes led to the formation of a vaginal septum. As a result, the proximal vagina and uterus could become compartmentalized and separated from the distal vagina. Affected patients presented with amenorrhea and hematocolpos. Diagnosis was made by demonstrating these findings on ultrasound. Intraoperative vaginoscopy was very important in such cases. Inability to visualize the cervix during intraoperative vaginoscopy confirmed the presence of a vaginal septum. These cases were treated with either laser incision of the septum or vaginal pull-through.

**Complete urethral loss**

This is the rarest type of injury and requires a vascularized flap for repair. This is most easily accomplished by making a bladder wall flap and tubularizing it to form a neo-urethra. There remains a high risk of incontinence. We carried out this procedure in only 1 patient.

Uroflow was performed after surgery to assess the success of the operation. Urinary continence was also assessed after surgery using a voiding diary.

**Results**

We retrieved the data of 22 patients: 10 girls (median age 9 years) and 12 women (median age 25 years). Median time from injury to surgery was 10 months. Urethral injury was in the proximal urethra in 5 cases (22.7%, 4 prepubertal girls and 1 adult woman), in the mid urethra in 10 cases (45.5%, 4 prepubertal girls and 6 adult women), and in the distal urethra in 6 cases (27.3%, 2 prepubertal girls and 4 adult women). One case presented with complete urethral loss ([Table 1](#)).

Of the 10 patients presenting with mid PFUI, 8 were approached transabdominally and 6 (2 girls and 4 adults) underwent urethrovaginal fistula repair. The approach was transvaginal in all 6 distal patients with PFUI. Two prepubertal girls with distal injury had vaginal introital stenosis and required vaginotomy. We observed a transverse vaginal septum that was attributed to trauma in 2 patients who both required vaginal pull-through. The patient with complete urethral loss needed a bladder

**TABLE 1.**  
Summary of treatments and outcome

No	Age at accident (years)	Interval to surgery (months)	Group	Mechanism of trauma	Associated injuries	Mode of treatment
1	5	3	Prepubertal	Collapsing wall	Urethrovaginal fistula	Delayed
2	2	36	Prepubertal	Collapsing wall	Urethrovaginal fistula	Delayed
3	9	4	Prepubertal	Road traffic accident	Urethrovaginal fistula	Delayed
4	10	6	Prepubertal	Road traffic accident	Urethrovaginal fistula, lower limb fractures, degloving injury in thigh	Delayed
5	11	4	Prepubertal	Road traffic accident	None	Delayed
6	10	3	Prepubertal	Road traffic accident	Urethrovaginal fistula, lower limb fracture	Delayed
7	43	24	Postpubertal	Road traffic accident	Urethrovaginal fistula	Delayed
8	23	6	Postpubertal	Road traffic accident	Lower limb fracture	Delayed
9	35	3	Postpubertal	Road traffic accident	None	Delayed
10	30	0 <sup>b</sup>	Postpubertal	Road traffic accident	Vaginal injury, lower limb fracture	Primary
11	22	10	Postpubertal	Road traffic accident	Vaginal injury	Delayed
12	5	11	Prepubertal	Road traffic accident	Vaginal stenosis	Delayed
13	21	3	Postpubertal	Road traffic accident	Lower limb fracture, complete urethral loss	Delayed
14	6	24 <sup>c</sup>	Prepubertal	Road traffic accident	Lower limb fracture, anterior vaginal wall loss	Delayed
15	26	37 <sup>d</sup>	Postpubertal	Road traffic accident	Urethrovaginal fistula	Delayed
16	24	10	Postpubertal	Road traffic accident	Lower limb fracture, vaginal stenosis	Delayed
17	27	14	Postpubertal	Road traffic accident	None	Delayed
18	21	11	Postpubertal	Road traffic accident	Urethrovaginal fistula	Delayed

UVF: urethro-vaginal fistula <sup>a</sup>Failed; <sup>b</sup>Immediately; <sup>c</sup>14 prior interventions before referral; <sup>d</sup>Prior Mitrofanoff

	Location of injury	Approach and surgery	Continence Day Night	Uroflow (mL/s)	Follow-up (months)	Further intervention	Final result
	Proximal	Abdominal, closure of UVF, anastomotic urethroplasty	Yes No	9	47	None	Success
	Proximal	Abdominal, closure of UVF, anastomotic urethroplasty	Yes Yes	0 <sup>a</sup>	36	Redo	Success
	Proximal	Abdominal, closure of UVF, anastomotic urethroplasty	Yes No	14	42	None	Success
	Mid	Abdominal, closure of UVF, anastomotic urethroplasty	Yes Yes	18	46	None	Success
	Mid	Abdominal, anastomotic urethroplasty	Yes Yes	16	63	None	Success
	Mid	Abdominal, closure of UVF, anastomotic urethroplasty	Yes Yes	20	80	None	Success
	Mid	Abdominal, closure of UVF, anastomotic urethroplasty	Yes Yes	16	66	None	Success
	Distal	Vaginal	Yes Yes	19	112	None	Success
	Mid	Vaginal	Yes Yes	20	132	None	Success
	Mid	Vaginal	Yes Yes	22	156	None	Success
	Distal	Vaginal, meatoplasty	Yes Yes	18	72	None	Success
	Distal	Vaginal, meatoplasty, vaginotomy	Yes No	11	60	Vaginal pull-through	Success
	Proximal, Mid, Distal	Abdominal, bladder flap	Yes No	6	37	None	Success
	Mid	Abdominal, closure of UVF, anastomotic urethroplasty, Martius flap with skin forming the anterior vaginal wall	Yes Yes	12	12	None	Success
	Mid	Abdominal, closure of UVF, anastomotic urethroplasty	Yes Yes	22	14	None	Success
	Distal	Vaginal, pedicled labial flap, vaginotomy	Yes No	14	48	None	Success
	Distal	Vaginal, urethroplasty with laser incision of vaginal septum	Yes Yes	14	24	Vaginal pull-through	Vaginal septum Amenorrhea
	Mid	Abdominal, closure of UVF, anastomotic urethroplasty	Yes Yes	22	32	None	Success

continued on page 84

TABLE 1.

Summary of treatments and outcome, *Cont'd*

No	Age at accident (years)	Interval to surgery (months)	Group	Mechanism of trauma	Associated injuries	Mode of treatment
19	38	22	Postpubertal	Road traffic accident	Urethrovaginal fistula, limb fracture	Delayed
20	9	11	Prepubertal	Road traffic accident	Urethrovaginal fistula	Delayed
21	10	10	Prepubertal	Road traffic accident	None	Delayed
22	24	9	Postpubertal	Fall from train	Urethrovaginal fistula	Delayed

UVF: urethro-vaginal fistula <sup>a</sup>Failed; <sup>b</sup>Immediately; <sup>c</sup>14 prior interventions before referral; <sup>d</sup>Prior Mitrofanoff

wall flap. One child needed a complex reconstruction with use of a Martius flap along with the overlying labial skin to reconstruct the vaginal wall.

Overall, 17 patients (77.3%) were continent at night and during the day. Of those with proximal PFUI, 3/5 patients (60%) were continent at night and during the day. The patient with bladder wall flap was continent but voided with low pressure. This patient's urethra was patent on urethroscopy, and there was no obstruction. The median postoperative Qmax was 18 mL/s. After a median follow-up of 36 months, 1 patient with proximal PFUI required a surgical revision but was continent thereafter.

## Discussion

Management of female PFUI is evolving slowly, and only a few reports are available in the literature. Ours is one of the largest reported series of such patients to date.

Usually, the injury goes unnoticed in the acute post trauma evaluation. It is recognized by the inability to catheterize the patient or the presence of acute urinary retention. Examination of the vulva needs the lithotomy position, which is challenging in the acute setting of trauma. In the series by Perry and Husmann[5], the patients presented with extravasation and persistent incontinence, which suggests that the urethral injuries were overlooked on initial evaluation.

The favored management strategy for PFUI is to place a suprapubic catheter in the acute setting, stabilize the patient, and perform a definitive repair after 3 months. Rarely, if there is an acute transection that is accessible, and no other injuries, a primary repair can be attempted in an adult female.

The true incidence of female urethral injuries is unknown. Pelvic fracture urethral injuries are generally less common in females[8]. Factors likely include the flexibility provided by the vagina, as well as the inherent elasticity of female urethra in adults. Podestá et al. reported a concurrent vaginal laceration in 75% to 87% of cases[13], which is consistent with the experience of Venn et al.[8]. Singh et al. described a case of urethral distraction defect causing complete urethrovaginal avulsion[14].

Venn et al. reported 12 female patients, aged 7 to 51, with urethral injuries[8]. Four had concomitant rectal injuries. In 5 cases urethral continuity was preserved because the urethral injury was longitudinal. Two of these 12 patients presented in follow-up with stress urinary incontinence. Although the cause of incontinence is unclear, the authors suggested a mixed etiology including direct urethral damage and damage to innervation.

In our study, the majority of patients were continent after urethroplasty, although 5 had nocturnal incontinence. The fear of incontinence should not deter the urologist from performing anastomotic urethroplasty in women with PFUI. An artificial urinary sphincter can even be considered[8], although this was not needed in our patients.

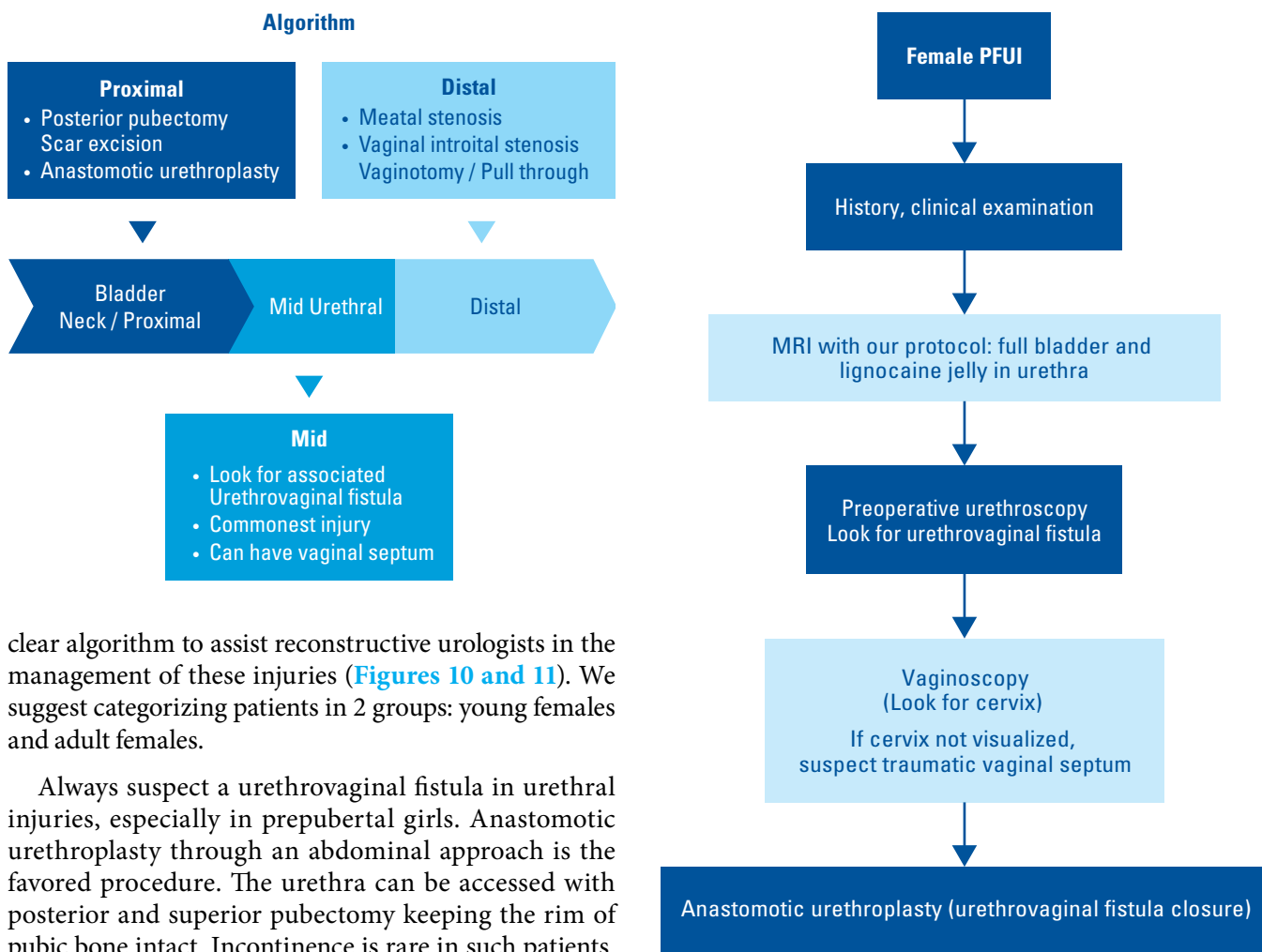
Over the last 2 decades, we have gained the greatest experience of male PFUI[10], and our experience with female PFUI has simultaneously grown. Female PFUI is particularly challenging to manage because of the diversity of urethral injuries observed. Venn et. suggested that it was difficult to produce recommendations on treatment of these injuries based on their patients. After operating on 22 such patients we are able to provide a



	Location of injury	Approach and surgery	Continenence Day Night	Uroflow (mL/s)	Follow-up (months)	Further intervention	Final result
	Proximal	Abdominal, closure of UVF, anastomotic urethroplasty	Yes Yes	21	18	None	Success
	Bladder neck	Abdominal, anastomotic urethroplasty	Yes Yes	19	12	None	Success
	Distal	Meatoplasty, vaginal pull-through	Yes Yes	11	12	None	Success
	Mid	Abdominal, anastomotic urethroplasty	Yes Yes	22	12	None	Success

FIGURE 10, FIGURE 11.

Algorithm for management of female pelvic fracture urethral injury



clear algorithm to assist reconstructive urologists in the management of these injuries (Figures 10 and 11). We suggest categorizing patients in 2 groups: young females and adult females.

Always suspect a urethrovaginal fistula in urethral injuries, especially in prepubertal girls. Anastomotic urethroplasty through an abdominal approach is the favored procedure. The urethra can be accessed with posterior and superior pubectomy keeping the rim of pubic bone intact. Incontinence is rare in such patients.

Few patients need a tailored approach to either lengthen the urethra if short or a full reconstruction in case of complete urethral loss. For these cases bladder or vaginal flaps are harvested for reconstruction. A bladder pubovaginal stenosis should be suspected in distal injuries. Such patients can present with amenorrhea and hematocolpos in the adolescent age. Scar excision, good tension-free anastomosis, and omental interposition are key steps in performing the anastomotic urethroplasty.

## References

1. Simpson-Smith A. Traumatic rupture of the urethra: eight personal cases with a review of 381 recorded ruptures. *Br J Surg.*1936;24:309–332.
2. Antoci JP, SchiC MR Jr. Bladder and urethral injuries in patients with pelvic fractures. *J Urol.*1982;128: 25–26. doi: 10.1016/s0022-5347(17)52734-2
3. Bredael JJ, Kramer SA, Cleeve LK, Webster GD. Traumatic rupture of the female urethra. *J Urol.*1979;122:560–561. doi: 10.1016/s0022-5347(17)56504-0
4. Patil U, Nesbitt R, Meyer R. Genitourinary tract injuries due to fracture of the pelvis in females: sequelae and their management. *Br J Urol.*1982;54:32–38.
5. Perry MO, Husmann DA. Urethral injuries in female subjects following pelvic fractures. *J Urol.*1992;147:139–143. doi: 10.1016/s0022-5347(17)37162-8
6. Barach E, Martin G, Tomlanovich M, Nowak R, Littleton R. Blunt pelvic trauma with urethral injury in the female: a case report and review of the literature. *J Emerg Med.*1984;2:101–105. doi: 10.1016/0736-4679(84)90328-7
7. Carter CT, Schafer N. Incidence of urethral disruption in females with traumatic pelvic fractures. *Am J Emerg Med.*1993;11:218–220. doi: 10.1016/0735-6757(93)90128-x.
8. Venn SN, Greenwell TJ, Mundy AR. Pelvic fracture injuries of the female urethra. *BJU Int.*1991;83:626–630. doi: 10.1046/j.1464-410x.1999.00001.x.
9. Kulkarni SB, Surana S, Desai DJ, Orabi H, Iyer S, Kulkarni J, et al. Management of complex and redo cases of pelvic fracture urethral injuries. *Asian J Urol.*2018 Apr;5(2):107–117. doi: 10.1016/j.ajur.2018.02.005. Epub 2018 Mar 2.
10. Joshi PM, Kulkarni SB. Management of pelvic fracture urethral injuries in the developing world. *World J Urol.*2020 Dec;38(12):3027–3034. doi: 10.1007/s00345-019-02918-0. Epub 2019 Aug 29.
11. Kulkarni SB, Joshi PM, Hunter C, Surana S, Shahrou W, Alhajeri F. Complex posterior urethral injury. *Arab J Urol.*2015 Mar;13(1):43–52. doi: 10.1016/j.aju.2014.11.008. Published online 2015 Jan 20.
12. Joshi PM, Desai DJ, Shah D, Joshi DP, Kulkarni SB. Magnetic resonance imaging procedure for pelvic fracture urethral injuries and recto urethral fistulas: a simplified protocol. *Turk J Urol.*2021 Jan;47(1):35–42. doi: 10.5152/tud.2020.20472. Epub 2021 Jan 1.
13. Podestá ML, Jordan GH. Pelvic fracture urethral injuries in girls. *J Urol.*2001 May;165(5):1660–1665.
14. Singh RK, Kaushal D, Khattar N, Nayyar R, Manasa T, Sood R. Pediatric pelvic fracture urethral distraction defect causing complete urethrovaginal avulsion. *Indian J Urol.*2018 Jan-Mar;34(1):76–78. doi: 10.4103/iju.IJU\_118\_17

## Conclusions

Female pelvic fracture urethral injuries are uncommon. When they occur, the commonest PFUI is the mid urethral avulsion. Urethrovaginal fistula should be suspected. The injury is best repaired with anastomotic urethroplasty, mostly through the abdominal approach, which we show leads to excellent outcomes. This surgery requires specialized expertise. We present here our experience of management of these injuries with an operative algorithm.